

# 3D Interactive Visualization and Volumetric Measurements of Coronary Vessels in IVUS

D.Rotger, C.Cañero, P.Radeva, J.Mauri†, E.Fernandez†, A.Tovar†, V.Vallet†  
University Autònoma of Barcelona. Computer Vision Center. Bellaterra (Barcelona).  
†Hospital Universitari Germans Trias i Pujol. Badalona (Barcelona).

## Abstract

Intravascular ultrasound images (IVUS) have allowed deepening in the knowledge of the true extension of the coronary vessel illness. Today, vessel diagnosis is limited to observation and measurements in the IVUS planes. For a bigger accuracy, 3D visualization is necessary to allow estimating the extension, localization and severity of the pathology. We develop tools for interactive 3D visualization to extend the views to any sailing angle through the cube of IVUS data. As a result, physicians are allowed to inspect and get 3D measurements about the vessel pathology from IVUS images.

**Keywords:** medical images, IVUS, 3D visualization, volumetric measurements.

## 1 Introduction

IVUS provide a unique 2D *in vivo* vision of the internal vessel walls, determining the extension, distribution and treatment of the atherosclerotic, fibrotic plaques and thrombus, and their possible repercussion on the internal arterial lumen. The main difference between the ultrasound and the angiography images (figure 1), as the most used image modalities for vessel diagnosis, deals with the fact that the most of the visible plaque lesions with IVUS are not evident with angiogram. Studies on intravascular ecography have shown that the reference vessel segment has the 35-40% of its sectional area occluded because of the plaque, although it appears as normal in the angiography [1]. Moreover, IVUS offer information about the composition of the internal lesion; in particular, about calcium deposits as the most important isolated predictors to evaluate if a particular lesion will respond to a catheter treatment. The possibility of visualizing directly the plaque by IVUS also benefits the receptors of a heart transplant; the IVUS have demonstrated that the 25% of the hearts to be transplanted are already ill.

IVUS are of particular interest in case of vessel therapy by stents. Intracoronary stent is a spiral metallic mesh that is implanted inside a vessel to save the stenosis effect (figure 1(b)) caused by a calcification or a grown of the intimal vessel layer. This mesh widens the vessel walls, recovering the necessary lumen for a good irrigation. The studies about stents carried out with IVUS show that the appearance in the angiography of a good stent deployment can hide two possible problems: the incomplete apposition (a portion of the stent is not making pressure on the vessel wall) and the incomplete expansion (a portion of the stent remains closed although the expansion of the rest of the stent areas). Both

problems are very significant since they can be worse than the problem they are trying to solve.

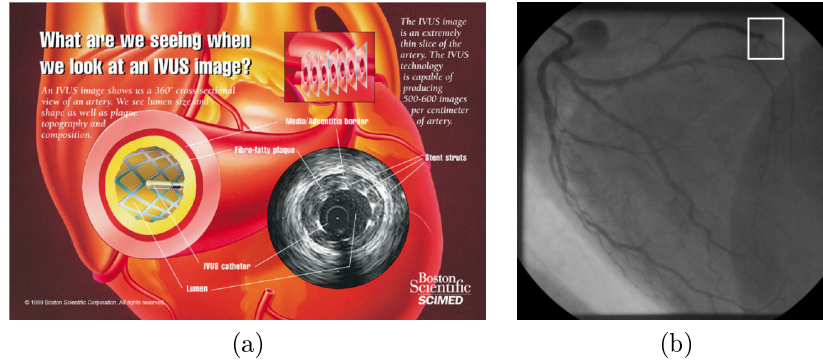


Figure 1: (a) IVUS image (reprint). (b) Angiography of a vessel with stenosis.

One of the problems of dealing with IVUS is the fact that the images represent a 2D plane perpendicular to the catheter without any depth information. This IVUS property hides the real disease's extension and represents a very unnatural way of conceptualization. The foremost limitation of IVUS on the pre- and post-treatment studies is the lesion images correlation in the serial studies. This limitation is due to the lack of the third dimension that gives much more global information about the internal and external vessel structure [2]. The third dimension allows a better knowledge of the vessel, the lumen and the plaque, visualizing simultaneously multiple sections of the vessel and obtaining a longitudinal perspective [6, 7]. The vessel can be later studied under multiple formats and different cut axes to interpret, in the space, a certain discovery, hardly esteemed from the two-dimensional images. To see the real extension of the lesion, we propose a navigation method based on cutting planes. These cuts allow passing in a continuous way from the traverse views to the longitudinal ones. The 3D reconstruction allows, for example, a more precise calculus of the size of the stent or the balloon to be implanted or make easier the election of better interventional instruments and their sizes. Three-dimensional images are synthesized by the sequential apposition of the two-dimensional ones. This kind of reconstruction presupposes the coronary section that we are treating as a straight line with the catheter transducer in the middle, determining the center of the lumen.

Taking measures of the volumetric vessel information is also a very important point. To this purpose IVUS data are completed by vessel and stent models to extract volumetric measurements about the vessel structures. According to the medical experts collaborating in this work, measuring the volume of the lumen before and after an intervention is good to evaluate the positive and/or negative effects that the intervention has provoked [3]. It helps to decide about further stent or angioplasty balloon interventions.

The article is organized as follows: section 2 discusses the 3D visualization for "navigating" inside the vessel; section 3 explains the process of extracting volumetric measurements by vessel model and IVUS data; the article finishes with conclusions and future work.

## 2 3D Visualization of Coronary Vessels

### 2.1 Cutting Planes Generation

Let us assume the IVUS data as a sequence of parallel planes, it can be seen as a cube. Hence, we can generate cutting planes under any spatial angle for better identification of calcium plaque and intimal layer grown. The possibility of cutting the data cube under any navigation angle allows passing in a continuous way from the traverse views to the longitudinal ones (figure 2). In a longitudinal cut of the section to study, the physician has a more accurate idea of the real extension of the lesion as well as a possibility to measure the stent size by pointing an initial and ending point.

To generate the cutting planes, we apply the two orthogonal vectors that are the generators of a plane containing the cut image. Initially, these two vectors have the X- and Y-axis direction of the central image of the cube. The intersection point of both vectors coincides with the catheter's center of this image. Applying rigid transformations (3D rotations and translations) to these two vectors, the physician is able to generate any plane contained in the data cube. [3]

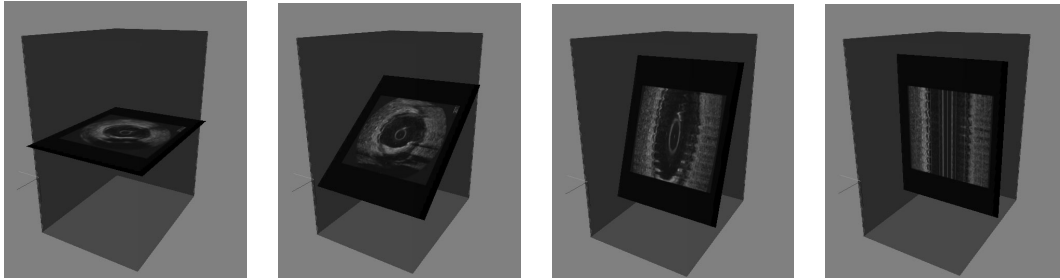


Figure 2: Cutting planes generation: continuous pass from the traverse views to the longitudinal ones.

If we define the center of the catheter, the translation vector and the central plane vectors as follows:

$$c = (c_x, c_y, c_z), \quad \vec{t} = (t_x, t_y, t_z), \quad \vec{v}_x = \begin{pmatrix} 1 \\ 0 \\ 0 \end{pmatrix}, \quad \vec{v}_y = \begin{pmatrix} 0 \\ 1 \\ 0 \end{pmatrix}$$

we are able to calculate all the generating vectors by the formulas:

$$\begin{aligned} \vec{v}_1 &= \mathbf{Rz} * \mathbf{Ry} * \mathbf{Rx} * v_x + \vec{t} \\ \vec{v}_2 &= \mathbf{Rz} * \mathbf{Ry} * \mathbf{Rx} * v_y + \vec{t} \end{aligned} \quad (1)$$

where  $\mathbf{Rx}, \mathbf{Ry}, \mathbf{Rz}$  are the third order rotation matrix. [8]

Taking into account the different horizontal and vertical calibration factors, we multiply each vector component by its calibration factor to assure the continuous way of passing from

the short-axes images to the long-axes ones:

$$\begin{aligned}\vec{v}'_1 &= \frac{\vec{v}_1}{\|\vec{v}_1\|}, & \vec{v}_1 &= (v'_{1x} * c_H, v'_{1y} * c_H, v'_{1z} * c_V) \\ \vec{v}'_2 &= \frac{\vec{v}_2}{\|\vec{v}_2\|}, & \vec{v}_2 &= (v'_{2x} * c_H, v'_{2y} * c_H, v'_{2z} * c_V)\end{aligned}$$

where  $c_H$  and  $c_V$  are the calibration factors.

When constructing the IVUS data cube, we should take into account the vessel dynamics at the time the catheter is doing its pullback i.e. the beating of the patient's heart. Ignoring the rotation of IVUS data in the image planes around the catheter leads to artifacts that can be appreciated in figure 3(a). This problem is avoided by estimating the rotation manually or automatically [5] and including it in the matrix  $Rz$  of formula (1). The correction of image rotation allows to obtain a continuous view of vessels in cutting planes under any spatial angle (figure 3(b)).

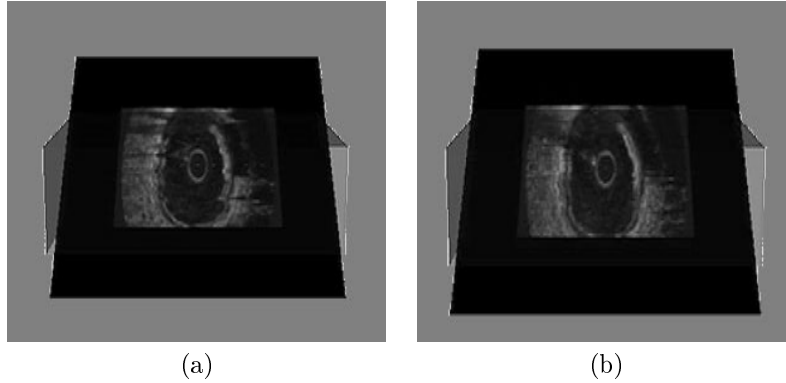


Figure 3: (a) Cut plane without rotation correction. (b) Cut plane with rotation correction

### 3 Extracting Volumetric Vessel Measurements

A model of the vessel wall and of the stent is very useful in order to determine its morphology in space, to extract volumetric measurements and to take decision about stent implantation. These models have been implemented by B-Splines because of their nice properties (easy to adapt to the vessel wall and stent, local control, model compactness, etc.)[9]. The models can be easily generated by determining the B-Spline control points that define a B-Spline curve to adjust manually or automatically [4] to vessel and stent boundary in each of the IVUS images (figure 4).

#### 3.1 Spatial Models

Once obtained B-Spline curves that represent vessel and stent boundaries, they are interpolated in space using B-Spline surfaces to construct a spatial model of the vessel and stent (figure 5(a)). [2, 9]

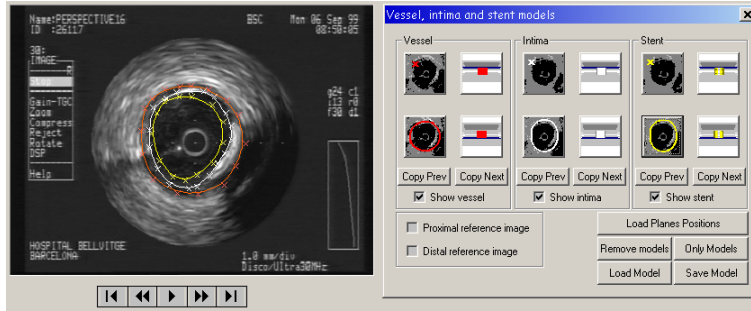


Figure 4: Vessel wall and stent curve models.

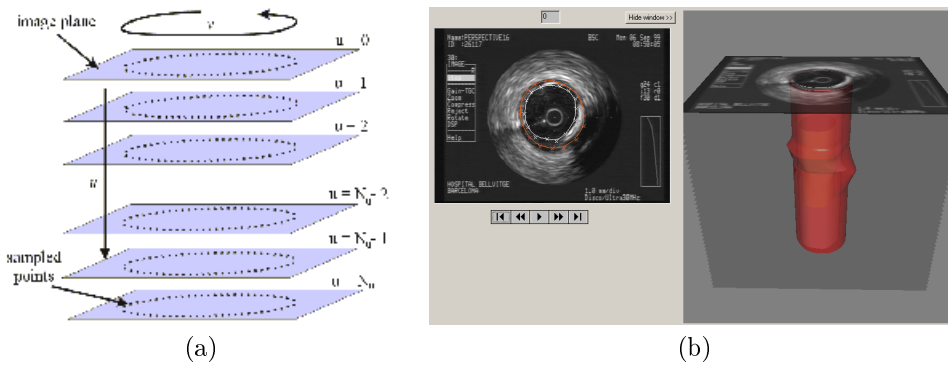


Figure 5: (a) Two-dimensional B-Spline model space generalization. (b) Spatial model of the vessel wall (the intimal layer) and the stent.

### 3.2 Measures Between the Vessel Wall and the Stent

As discussed above, extracting volumetric information is very important in order to evaluate intervention effects. Until now, area and distance calculus in IVUS planes have been the only possible ones carried out with IVUS images. Having a B-Spline representation of vessel and stent, it is easy to estimate the distance between them using a filling algorithm (Y-X, for example) in the images with drawn vessel and stent models. Then, we can calculate the area of each model in pixels and infer the intersection area:

$$s = c_H^2 * (a_v - a_s)$$

where  $c_H$  is the horizontal calibration,  $a_v$  and  $a_s$  are the area of the vessel and the stent.

We extrapolate the area calculus to the space, using trapezoids, to get the volumetric measurement as follows:

$$V = |s_i - s_{i+1}| * c_V$$

where  $c_V$  is the vertical calibration defined by the pullback speed (the distance in millimeters between 2 images) and the  $s_i$  and  $s_{i+1}$  are the intersection areas of two consecutive planes.

## 4 Results and Conclusions

The implemented tools for 3D interactive visualization of vessel morphology is of great clinical interest [3] making easier the conceptualization process of vessel diagnosis and therapy. Until now, clinical comparisons of different pullbacks of a patient limit to compare distances and areas of a selected IVUS image trying to figure out the severity of vessel pathology in space. As a result of this work, the medical doctors have a tool to see the real extension of the coronary disease not in an image or a sequence but in space as well as to measure more accurately its effect. Currently, the project is under clinical validation, extracting information from a statistic number of patients and comparing previous results with the new ones to estimate the importance of volumetric vessel measurements. A natural extension of this work includes creating a virtual reality environment for realistic navigation and interaction with the vessel as well as simulating vessel interventions, implementing the automatic correction of the vessel rotation and automatic segmentation of the vessel layers.

## References

- [1] Morton J. Kern. *The Cardiac Catheterization Handbook*, 1992.
- [2] Oriol Pujol. *Model-based Three Dimensional Interpolation of IVUS Images*, Master's thesis, Computer Vision Center, 1999.
- [3] Mauri, FN, Valle, Esplugas, Cequier, Rotger et al. *Ecografia Intracoronaria: Navegación Informática por el Cubo de Datos de las Imágenes*, Congreso de la Sociedad Española de Cardiología, Granada, 2000.
- [4] D. Gil, P. Radeva, J. Saludes, *Segmentation of artery wall in coronary IVUS images: A probabilistic approach*, 15 th International Conference on Pattern Recognition, Barcelona, 4:352-355, 2000.
- [5] J. Mauri, E-F. Nofreras, D. Gil et al. *Moviment del vas en l'anàlisi d'imatges de ecografia intracoronaria: un model matemàtic*, Congrés de la Societat Catalana de Cardiologia, Barcelona, 2000.
- [6] Von Birgelen C., Slager C., Di Mario C., de Feyter PJ., Serruys W., *Volumetric Intracoronary Ultrasound "A New Maximum Progression-Regression of Atherosclerosis*, Atherosclerosis 118 Suppl., 1995.
- [7] C. Von Birgelen, Mario C.D., Li W. Et al. *Morphometric Analysis in Three-Dimensional Intracoronary Ultrasound during Stent Deployment*, American Heart Journal, 1996, Vol.132, pp.516-527.
- [8] Juan Jose Villanueva. *Computer Graphics I manual*, Computer Vision Center, University Autonoma of Barcelona, 1996.
- [9] Brian A. Barsky, Richard H.Bartels, John C.Beatty. *An Introduction to Splines for use in Computer Graphics and Geometry Modeling*. Morgan Kaufmann Publishers INC, 1987.